



PATIENT

Ms L Gonsalves

SPECIES

Feline

BREED

DMH

SEX

Female Spayed

AGE

10 years

WEIGHT

5.88lbs

INTERPRETED BY

Maggie Machen
Lamy, DVM
DACVIM (Cardiology)

IMAGING

PERFORMED BY

Pamela Harrigan,
RDCS

HOSPITAL NAME

Anchor Animal
Hospital

REFERRING VET

Dr. Pietsch

INVOICE

20649

DATE

8/19/21

PRESENTING CLINICAL SIGNS

History: Patient has a mammary mass. Radiographs show enlarged heart. She had bradycardia and developed crackles in her lungs when under anesthesia - she recovered well. On recheck exam, dropped beats were noted (new finding). ProBNP normal. Average BP: 200-220bpm.

ELECTROCARDIOGRAPHIC FINDINGS *Note: Single lead ECGs are evaluated as a rhythm strip. Morphology/MEA cannot be definitively commented on.

A single lead ECG is available; 25mm/s, 20mm/mV. The average heart rate is 190bpm with a largely regular rhythm. The rhythm is sinus in origin, with a p for every QRS complex and vice versa. P and QRS morphologies are positive. No ectopic beats, pauses or dysrhythmias observed.

ECG diagnosis: Normal sinus tachycardia.

ECHOCARDIOGRAM FINDINGS

2D, m-mode, color flow and Doppler imaging is available.

Left ventricle: The LV diameter is normal with adequate myocardial function. The LV wall thicknesses are normal. The endocardium is normal. False tendon. The papillary muscles are mildly remodeled and hyperechoic.

Left atrium: The left atrium is normal in dimension. No obvious spontaneous contrast or thrombi seen.

Mitral valve: The mitral valve is normal in structure and mobility. No obvious systolic anterior motion is seen.

Aortic valve/Aorta: The aortic valve is normal in morphology and mobility. Normal aortic outflow velocity; laminar flow. No aortic insufficiency.

Right ventricle: Normal right ventricular diameter and morphology indicating no overt evidence of pulmonary arterial hypertension.

Right atrium: The right atrium is normal in dimension.

Tricuspid valve: The tricuspid valve appears normal with trace tricuspid regurgitation. Normal velocity.

Pulmonic valve/Pulmonary artery: The pulmonic valve is normal in morphology and mobility. No pulmonic insufficiency. Normal RVOT velocity; laminar flow.

Pericardium/other: No pericardial or pleural effusion noted. No obvious cardiac masses.

2-Dimensional Measurements

Ao diam (cm)	1.0
LA diam (cm)	1.1
LA:Ao (Swe)	1.1
IVS thickness (cm)	0.47
LVID diastole (cm)	1.4
PW thickness (cm)	0.47
LVID systole (cm)	0.7
FS (%)	49

Doppler Measurements

PV Vmax (m/s)	0.8
AoV Vmax (m/s)	1.1
MR Vmax (m/s)	NA
TR Vmax (m/s)	1.3
TR PG (mmHg)	7



PATIENT

Ms L Gonsalves

SPECIES

Feline

BREED

DMH

SEX

Female Spayed

AGE

10 years

WEIGHT

5.88lbs

INTERPRETED BY

Maggie Machen
Lamy, DVM
DACVIM (Cardiology)

IMAGING PERFORMED BY

Pamela Harrigan,
RDCS

HOSPITAL NAME

Anchor Animal
Hospital

REFERRING VET

Dr. Pietsch

INVOICE

20649

DATE

8/19/21

INTERPRETATION OF THE FINDINGS

Overtly normal cardiac structure and function. The LV wall thickness is normal and there is no clear evidence of elevated left atrial pressure. There is mild remodeling and fibrosis which is considered normal. No additional issues are identified.

The ECG is also unremarkable with a sinus tachycardia. No premature beats or pauses are identified; however, these still may persist uncaptured. A longer tracing or potentially a holter monitor should be considered depending on the personality of the cat.

Given these findings, there is no obvious structural or arrhythmic reason for the anesthetic event. Consider other possibilities such as a drug reaction. Consultation with an Anesthesiologist may be useful before proceeding in the future.

The reported blood pressure is elevated and should be reassessed for accuracy particularly given no reported clinical signs of severe hypertension (retinal changes, etc.) or evidence of LVH on echo. Ideally obtain serial measurements in a controlled, low stress environment and continue until 3 consecutive readings plateau within 5mmHg of variability. If persistently >180mmHg despite a relatively calm demeanor, recommend institution of amlodipine to effect. Additionally, if deemed accurate, screening for predisposing underlying causes of SHT is recommended (Cushings, PLN, adrenal tumor, etc.), as primary disease is relatively uncommon and a rule out diagnosis.

RECOMMENDATIONS

- Given these findings, no medications are indicated.
- Reassess BP as discussed.
- No cardiac contraindication for general anesthesia is seen here. If premature beats persist, anesthetic risk is considered mildly elevated. Avoid ketamine, telazol, dexdomitor (or other alpha-2 agonists) and acepromazine. Recommend having lidocaine CRI available for use in the event of sustained ventricular arrhythmias under anesthesia (CRI 50—75mcg/kg/min).
- Monitor for any clinical evidence of cardiac compromise, including respiratory changes and/or signs of a blood clot event (paralysis, neurologic changes, etc.).

PLAN

- Recommend recheck echocardiogram in 1 year, sooner if a murmur or gallop develop in the future, or clinical signs of cardiac compromise are noted.



PATIENT

Ms L Gonsalves

SPECIES

Feline

BREED

DMH

SEX

Female Spayed

AGE

10 years

WEIGHT

5.88lbs

INTERPRETED BY

Maggie Machen
 Lamy, DVM
 DACVIM (Cardiology)

**IMAGING
 PERFORMED BY**

Pamela Harrigan,
 RDCS

HOSPITAL NAME

Anchor Animal
 Hospital

REFERRING VET

Dr. Pietsch

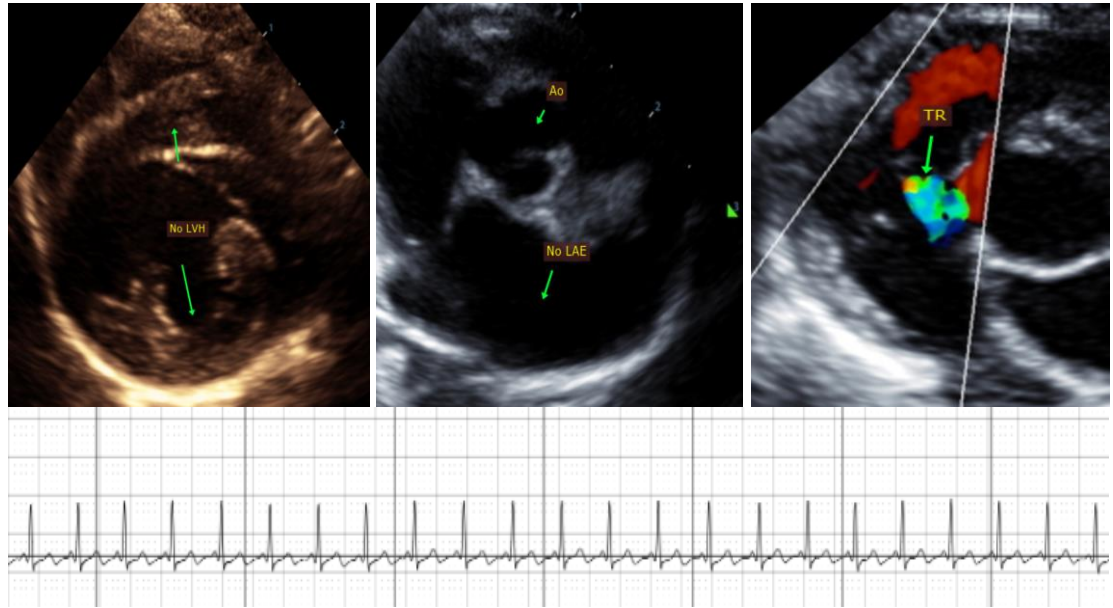
INVOICE

20649

DATE

8/19/21

IMAGES



The information and recommendations provided are based on the images presented by the referring veterinarian. No evaluation can be communicated regarding pathology that was not visible in the image/video clips provided.

Thank you for this referral. This report was generated using transcription software, and minor dictation errors may be present. If the clinical or image interpretation does not parallel your findings or if I can be of any further assistance, please contact me.

Maggie Machen Lamy, DVM
Diplomate of the American College of Veterinary Internal Medicine (Cardiology)
 info@sonopath.com